



Diagnosing a GIST and Deviating from Tradition: A Case Study

Penelope Kagan, BA, OMS-II,¹ Laura Schoerning, BA, OMS-III,¹ Michael G. Rowe, MD²

¹Marian University College of Osteopathic Medicine, Indianapolis, IN, USA ² Department of General Surgery, St. Vincent Hospital, Indianapolis, IN, USA

GIST so you know...

- Gastrointestinal stromal tumors (GISTs) are the most common mesenchymal tumor of the abdomen, most frequently found in the stomach or proximal small intestine
- GISTs are often an incidental finding during radiology, endoscopy, or abdominal surgery due to their inconspicuous or non-specific nature and low malignant potential.
- The term **stromal** reflects historical confusion about the origin of this tumor, which is now recognized to arise from the interstitial cells of Cajal, or pacemaker cells, of the gastrointestinal muscularis propria.
- Approximately 75% to 80% of all GISTs have oncogenic, gain-of-function mutations in the receptor tyrosine kinase KIT(CD117).
- Prognosis correlates with tumor size, mitotic index, and location.

Epidemiology

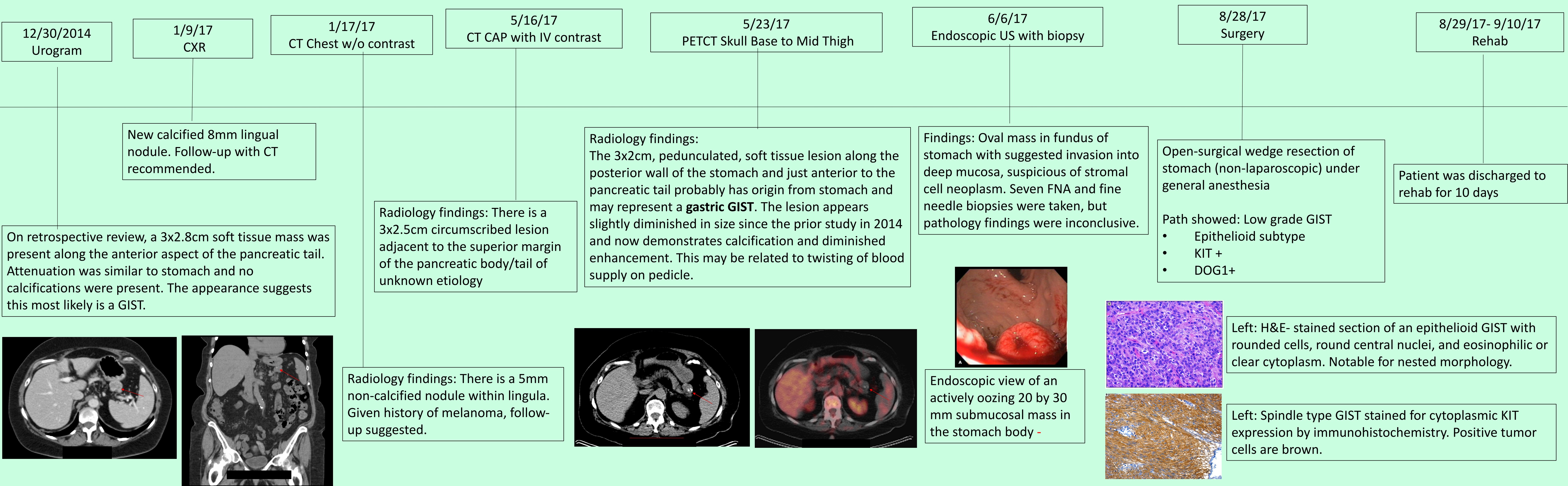
- Annual incidence is between 11 and 20 cases per million people.
- Occur in middle age or older individuals (>40 yrs). Mean age at diagnosis is 64.

Diagnosis & Treatment

- Diagnosing a GIST preoperatively is challenging, as endoscopic biopsies often do not obtain sufficient tissue and imaging often yields non-diagnostic findings.
- CT scan with contrast is the preferred diagnostic imaging study for screening and staging.
- PET scanning is not sufficiently specific to make a preoperative diagnosis.
- Preoperative biopsy is not generally recommended for a resectable lesion in which there is a high suspicion for GIST and the patient is otherwise operable. However, a biopsy is preferred to confirm the diagnosis if metastatic disease is suspected.
- All GISTs ≥ 2 cm in size should be surgically resected.
- Imatinib for 1 year duration is approved for adjuvant treatment of GISTs ≥ 3 cm in size.

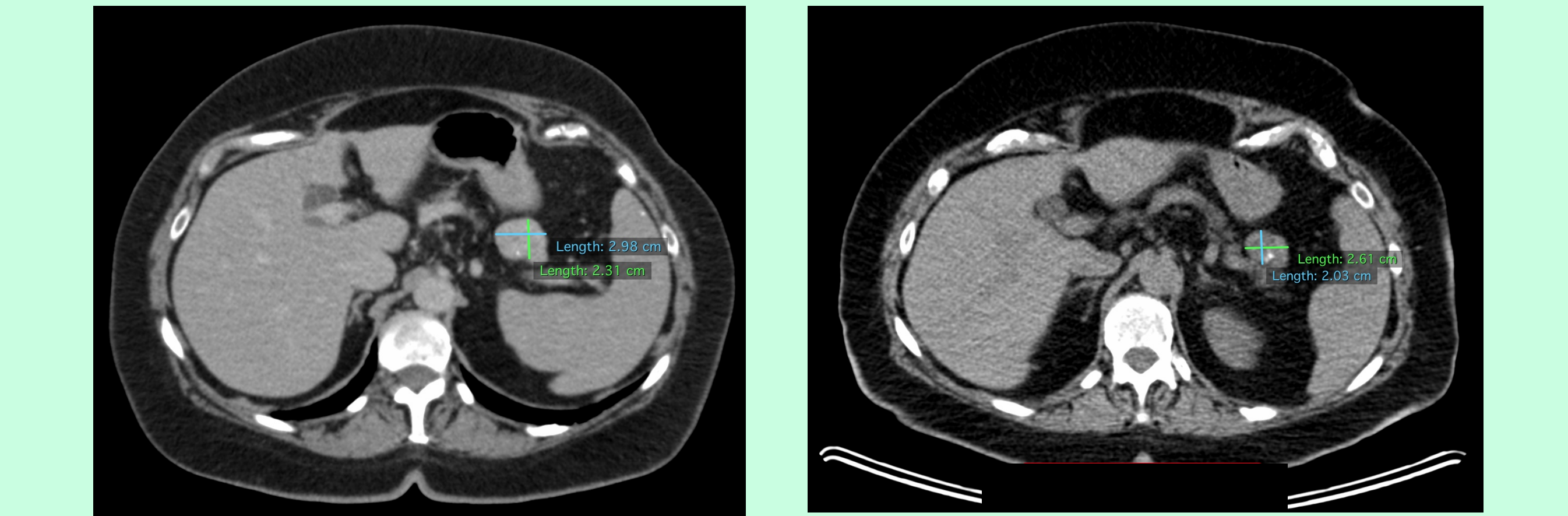
Clinical case:

- An 80 yo female with a history significant for:
 - Resected melanoma in 2001
 - Shingles affecting larynx and esophagus in APR 2013 with two years of ongoing neuralgia
- Annual CXRs were performed for surveillance based on her history of melanoma.
- Her **CXR performed in Jan 2017** showed a new lingual lesion prompting a follow-up CT Chest scan to be done. Based on the CT chest results, continued follow-up of the lingual nodule was recommended.
- CT CAP was done in May 2017.** While the stable lingual nodule was presumed benign or postinflammatory, a 3x2.5cm circumscribed, partially calcified mass was seen adjacent to greater curvature of stomach, near the pancreatic tail. Although not noted in the previous report, the lesion was present on the prior chest CT from Jan 2017. Comparatively, the stomach lesion was unchanged in size. Continued follow-up and comparison to more remote prior imaging to assess the extent of the stability was encouraged.
- Her oncologist ordered a PETCT to further evaluate the stomach mass. **PETCT** was done at an outside center that also possessed images from a urogram done in 2014. Again, although the report from 2014 made no mention of the lesion, review of the images showed a similarly sized lesion adjacent to the pancreatic tail. Based on the PETCT findings and comparison to the 2014 images, a diagnosis of a GIST was suggested.
- The patient was referred to a surgeon. The surgeon recommended an **Upper Endoscopic Ultrasound with Biopsy** under general anesthesia. The endosonographic appearance was highly suspicious of a GIST. NxMx by endosonographic criteria. FNA and fine needle biopsies were performed, however pathology results were inconclusive due to insufficient cellular material.
- The surgeon recommended a laparoscopic resection of the tumor, however, concerned about the potential for malignancy, the patient requested an open approach.
- Open-surgical wedge resection of the stomach tumor** under general anesthesia was performed in August 2017. Final diagnosis was made of a low grade, epithelioid GIST that was KIT+ and DOG1+.
- Patient was **discharged to rehab** for ten days after her surgery.



How long had the GIST been there?

These side by side images demonstrate the stability of the patient's tumor between December 2014 and May 2017. Left image: Measurements of the lesion obtained from a CT urogram performed in December 2014 were 3x2.8cm. Right image: Measurements of the lesion obtained from a PETCT performed in May 2017 were 3x2cm. No comment was made on this lesion in the original CT urogram report from December 2014. Consequently, neither the patient nor PCP had knowledge of the lesion. Both scans demonstrated low attenuation. Notable changes included new calcifications and diminished enhancement. Calcifications in GIST tumors are unusual, but can occur.



Discussion/Conclusion:

- Why wasn't the lesion noted on the Urogram report in 2014 or in the Chest CT in Jan 2017?
- Was unnecessary testing done in search of a preoperative diagnosis?
- Should open surgery have been performed? While current research recommends surgical resection of GISTs >2cm, the patient's tumor could have been resected laparoscopically (although she requested open surgery).
- In an 80-year-old, widowed, female on Medicare, was surgical resection of the tumor necessary given its 3+ year stability?
- Were diagnosis assessments and surgical removal worth the risks that they posed to the patient, and the psychological and financial burden placed on the patient?
- What are potential problems associated with having imaging done at multiple centers and how can these problems be mitigated?

References

- Kumar, V., Abbas, A.K. (2015). *Robbins and Cotran Pathologic Basis of Disease*. Retrived from <https://www.clinicalkey.com/#/browse/book/3-s2.0-C20110055734>
- Up To Date*. (2017, December 21). Retrieved March 18, 2018, from https://www.uptodate.com/contents/epidemiology-classification-clinical-presentation-prognostic-features-and-diagnostic-work-up-of-gastrointestinal-stromal-tumors-gist?search=GIST&source=search_result&selectedTitle=1~79&usage_type=default&display_rank=1#H1482891848
- Up To Date*. (2017, September 13). Retrieved March 18, 2018, from https://www.uptodate.com/contents/local-treatment-for-gastrointestinal-stromal-tumors-leiomyomas-and-leiomyosarcomas-of-the-gastrointestinal-tract?search=GIST%20treatment&source=search_result&selectedTitle=1~79&usage_type=default&display_rank=1