

7-2018

# Superficial Ulnar Artery with High Bifurcation of the Brachial Artery and its Clinical Significance

Jacob Sieger OMS-2

*Marian University - Indianapolis*

Lajja Patel OMS-2

*Marian University - Indianapolis*

Emily Parker OMS-2

*Marian University - Indianapolis*

Max Sheng OMS-2

*Marian University - Indianapolis*

Kabir Sheikh OMS-2

*Marian University - Indianapolis*

*See next page for additional authors*

Follow this and additional works at: [https://mushare.marian.edu/mucom\\_spr](https://mushare.marian.edu/mucom_spr)



Part of the [Cardiovascular System Commons](#)

## Recommended Citation

Sieger, Jacob OMS-2; Patel, Lajja OMS-2; Parker, Emily OMS-2; Sheng, Max OMS-2; Sheikh OMS-2, Kabir; and Sakthi Velavan, Sumathilatha MBBS, DGO, MS, "Superficial Ulnar Artery with High Bifurcation of the Brachial Artery and its Clinical Significance" (2018). *Student Publications and Research*. 20.  
[https://mushare.marian.edu/mucom\\_spr/20](https://mushare.marian.edu/mucom_spr/20)

This Poster is brought to you for free and open access by the College of Osteopathic Medicine at MUShare. It has been accepted for inclusion in Student Publications and Research by an authorized administrator of MUShare. For more information, please contact [emandity@marian.edu](mailto:emandity@marian.edu).

---

**Authors**

Jacob Sieger OMS-2; Lajja Patel OMS-2; Emily Parker OMS-2; Max Sheng OMS-2; Kabir Sheikh OMS-2;  
and Sumathilatha Sakthi Velavan MBBS, DGO, MS



# Superficial Ulnar Artery with High Bifurcation of the Brachial Artery and its Clinical Significance

SIEGER, Jacob, Lajja PATEL, Kabir SHEIKH, Emily PARKER, Max SHENG, and Sumathilatha SAKTHI VELAVAN.  
Department of Biomedical Sciences, Marian University College of Osteopathic Medicine, Indianapolis, IN, 46222, USA.

## Introduction

Although the variations in brachial artery branching patterns are commonly observed, only 3.75% exhibit a high ulnar artery variation<sup>1</sup>. An even fewer number present with a bilateral superficial ulnar artery, as was reported by Fadel and Amonoo-Kuofi<sup>2</sup>. The compounding variations of a high bifurcation of the brachial artery and a superficial ulnar artery may be asymptomatic, but demonstrate important clinical significance in relation to accidental intra-arterial injections, errors in blood pressure readings, as well as orthopedic, plastic and vascular surgeries of the upper limbs<sup>1</sup>. This study aims to expand upon previous literature and provide additional insight to the field of clinical anatomy, while educating physicians of the possible presentations and potentially severe risks associated with these variations.

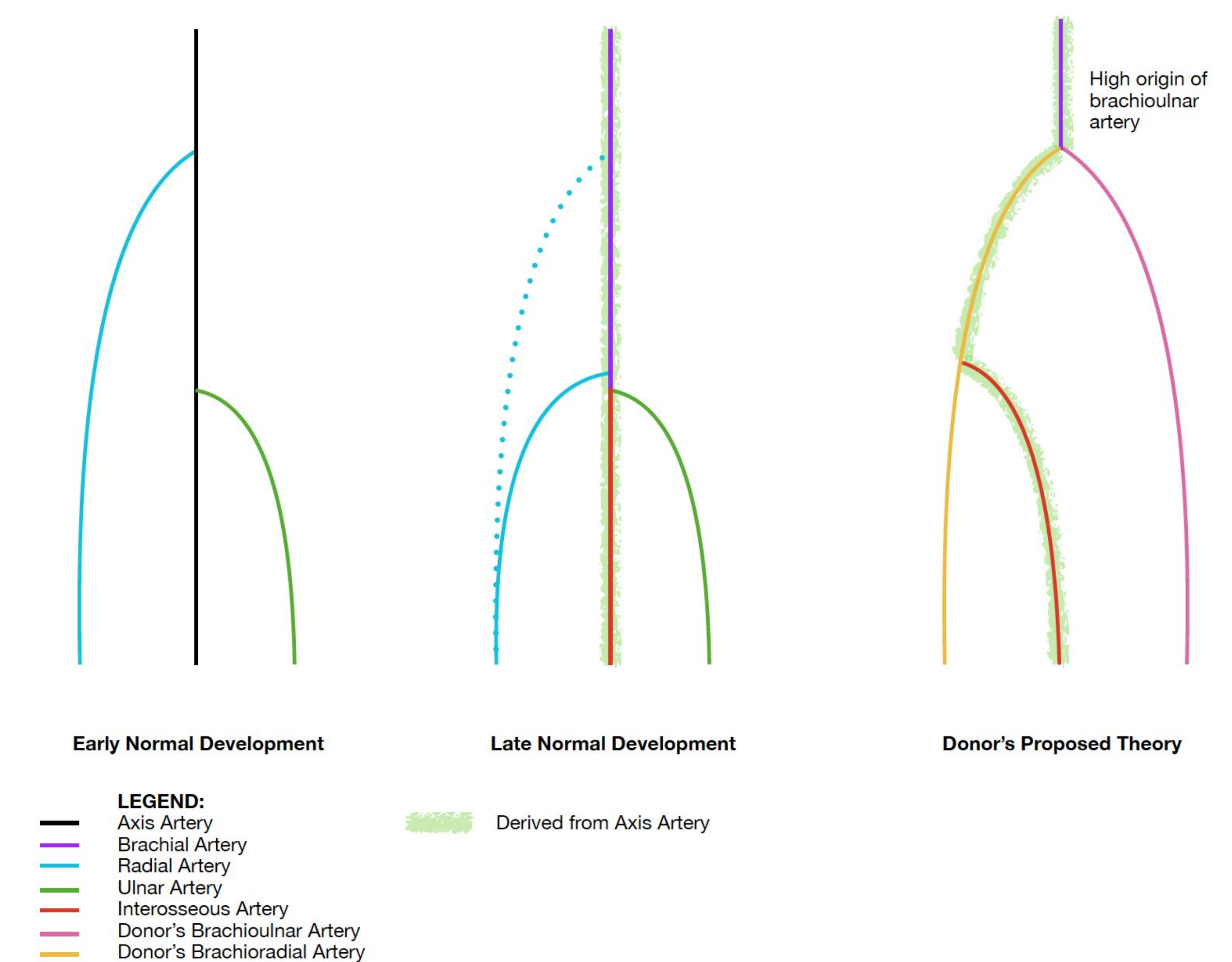
## Resources

A dissection was performed of the upper limbs on an 84-year-old caucasian male cadaver. The brachial artery terminated atypically high on the arm, and care was taken to preserve the course of the arteries through the remainder of the upper limb.

## Description

- High bifurcation of the brachial artery occurred bilaterally at the proximal one-third of each arm.
- Both (brachio)radial arteries were larger than their respective (brachio)ulnar arteries.
- The (brachio)radial arteries gave origin to the common interosseous arteries.
- The (brachio)ulnar artery traversed medial to the median nerve in the cubital fossa, continuing superficial to all forearm muscles except the palmaris longus tendon [Fig. 1].


## Embryogenesis of Upper Limb Arteries



**Figure 2.** Normal and proposed embryogenesis of donor.

## Significance

- The brachial artery develops as a branch from the main trunk of the axis artery and gives off the branches of the radial and ulnar arteries through the cubital fossa<sup>2,3</sup> [Fig. 2].
- Variable developmental hemodynamics during angiogenic sprouting may yield primitive vasculature which persists, fuses, absorbs or regress in unusual patterns<sup>3</sup>.
- Possible intra-arterial injection of drugs due to the proximity of normal vein puncture sites has been reported as well as possible arteriographic misinterpretations when the contrast dye is injected distal to the origin of these variant arteries<sup>1</sup>.
- Variant high origin of ulnar artery as in the present case with small caliber as compared that to radial artery should be known to surgeons performing free radial forearm flap, as the blood supply of forearm after surgery would depend entirely on the variant ulnar artery<sup>4</sup>.
- With the median nerve interposed between the radial and ulnar arteries, simple clinical procedures such as blood pressure recording could become a complicated ordeal<sup>5</sup>.



**Figure 1.** Right (above) and left (below) upper limbs.

1. Brachial Artery
2. (Brachio)radial Artery
3. (Brachio)ulnar Artery
4. Common Interosseous Artery
5. Superficial Palmar Arch
6. Median Nerve
7. Ulnar Nerve
8. Musculocutaneous Nerve
9. Coracobrachialis
10. Biceps Brachii
11. Triceps Brachii
12. Brachioradialis
13. Pronator Teres (cut)
14. Flexor Carpi Radialis
15. Palmaris Longus
16. Flexor Carpi Ulnaris
17. Flexor Digitorum Superficialis
18. Flexor Pollicis Longus
19. Anterior Interosseous Artery

## References

1. Rodriguez-Niedenfuhr M, Vazquez T, Parkin IG, Sanudo JR. Arterial patterns of the human upper limb: update of anatomical variations and embryological development. *Eur J Anat* 2003; 7 (Suppl. 1): 21–8
2. Fadel, Raouf & Amonoo-Kuofi, Harold. (1996). The superficial ulnar artery: Development and surgical significance. *Clinical anatomy*. 9. 128-32. 10.1002/(SICI)1098-2353(1996)9:2<128::AID-CA5>3.0.CO;2-D.
3. Saraswathi P, Christy AJ, Sainath S. High bifurcation of the radial and ulnar artery from the brachial artery: case report. *Int J Anat Var*. 2017;10(2):26-7.
4. Swamy RS, Rao M, Kumar N, Sirasanagandla SR, Nelluri VM. Unusual branching pattern of axillary artery associated with the high origin of ulnar artery. *Ann Med Health Sci Res* 2013;3:265-7.
5. Mehta V, Arora J, Suri RK, Rath G. Unilateral Anomalous Arterial Pattern of Human Upper Limb: Anatomical Description and Clinical Implications. *Sultan Qaboos University Medical Journal*. 2008;8(2):227-230.

## Acknowledgments

The authors would like to thank the donor and his family, the Department of Biomedical Sciences and Research Club of Marian University College of Osteopathic Medicine for their support and assistance.